

## MANAGEMENT OF INTUSSUSCEPTION IN PEDIATRIC POPULATION AT A TERTIARY CARE CENTER

David Thanka Edison<sup>1</sup>, Ananthan M<sup>1</sup>, VV Kannan<sup>1</sup>, Praveen Krishna G<sup>1</sup>, Mithun Govind<sup>1</sup>

<sup>1</sup>Department of Paediatric Surgery, Tirunelveli Medical College Hospital, India

Received : 01/01/2024  
Received in revised form : 09/02/2024  
Accepted : 27/02/2024

**Keywords:**

Intussusception, Hydrostatic reduction, ultrasound guided saline reduction.

**Corresponding Author:**

**Dr. Praveen Krishna G,**  
Email: drpraveen.krishnag@gmail.com

DOI: 10.47009/jamp.2024.6.1.293

Source of Support: Nil,  
Conflict of Interest: None declared

*Int J Acad Med Pharm*  
2024; 6 (1); 1467-1472



### Abstract

**Background:** Intussusception is a common cause of intestinal obstruction in children, which requires prompt diagnosis and treatment in order to prevent, loss of bowel segment due to necrosis. Non operative management of intussusception is the treatment of choice. The aim of the study was to evaluate the efficiency of ultrasound guided hydrostatic reduction in treating intussusception. The purpose of this study was to evaluate the clinical picture of cases undergoing USG guided hydrostatic reduction and to assess its outcome.

**Materials and Methods:** We conducted a retrospective study of intussusception cases who underwent USG guided hydrostatic reduction in our department of paediatric surgery, Tirunelveli medical college during the period of September 2021 to August 2023. A total 88 cases were included in the study.

**Result:** Mean age of the study participants was found to be 15.3±10.5 months with notable male predominance. Most common symptoms reported in this study was abdominal pain (76.1%) followed by vomiting (65.9%), abdominal distension (44.3%), blood in stools (35.2%), constipation (43.2%) and diarrhea (34.1%). All the cases underwent USG hydrostatic reduction however the success rate was reported as 85.2% and the rest of the cases underwent open manual reduction or resection anastomosis. Mean duration of stay in hospital was reported as 5.3±2.6 days and notably there were no mortality reported.

**Conclusion:** Ultrasound guided hydrostatic reduction is effective treatment modality option for intussusception, with high success rate & less morbidity.

## INTRODUCTION

Acute intestinal obstruction in infants is frequently caused by intussusception; infrequently, it also affects older kids and adults.<sup>[1]</sup> It can be described as the 'telescopic' advancement of the proximal intestine segment into the distal intestinal segment, and it is a significant cause of bowel blockage in children. Although ileo-ileal or colo-colic versions of the condition can also occur, ileo-colic intussusception is the most typical.<sup>[2]</sup> Although intussusception is more frequent in patients between the ages of 6 months and 3 years old, it can happen to anyone of any age.<sup>[3]</sup> Most of the time, no substantial cause can be found. Rarely, underlying lesions may operate as a lead point to induce intussusception in 2–50% of patients, and the prevalence of underlying lesions is higher in older age groups.<sup>[4]</sup> In one study from India,<sup>[5]</sup> intussusception was the cause of 16% of all intestinal blockage in children. Despite the significant prevalence of infectious diarrheal illnesses in infants seen in these locations,<sup>[1,5]</sup> intussusception is very infrequent in Asia and Africa for unknown reasons. A first attempt at non-operative

reduction of intussusception is made with a barium enema, saline water enema, or air-insufflation into the rectum; failure of subsequent attempts or evidence of peritonitis are grounds for surgery. The risk of subsequent peritonitis, sepsis, and intestinal perforation makes early identification and intervention crucial. Ultrasonography (US) is frequently used to make diagnoses with a sensitivity and specificity of around 98%.<sup>[6,7]</sup>

With highest specificity and a sensitivity for intussusception diagnoses, ultrasound is quite reliable.<sup>[8,9]</sup> Colour Doppler ultrasound appears to be an effective method for detecting the vascular alterations associated with intussusception and may be a good indicator of bowel necrosis.<sup>[10]</sup> Once intussusception has been diagnosed, non-operative reduction is the main goal. Utilising air, saline, barium, oxygen, water, and water soluble iodinated contrast material under fluoroscopic supervision results in the non-operative decrease of intussusceptions.<sup>[11]</sup> The use of air in reducing intussusception has been covered in a number of articles.<sup>[12]</sup> Recent years have seen a significant increase in the acceptance of ultrasound-guided

saline reduction as the initial method utilised for both the evaluation and non-operative treatment of children with intussusception. At different facilities, this modality's effectiveness rate varies, however it is often about 80%.<sup>[13]</sup> The patient goes through a number of clinical alterations in addition to radiological changes during the reduction. With this technique, both clinical and surgical end goals are used to measure success. When radiologists and physicians work together, the diagnosis of intussusception can be made with more accuracy, and it can be treated more successfully.

Each treatment has supporters and opponents; the ideal methodology, imaging modality, patient selection criteria, and recommended protocol are still up for debate. Although there are numerous research from western nations that detail the experience of treating intussusception with hydrostatic reduction, there are very few series published from India.

## MATERIALS AND METHODS

Retrospective study was carried out on intussusception patients of Department of Paediatric surgery at Tirunelveli Medical college Hospital, from Jan 2022 to June 2023. A total of 42 patients (both male and females) of aged  $\geq 18$ , years were for in this study.

**Study Design:** Retrospective study.

**Study Location:** This was a tertiary care teaching hospital based study done in Department of Paediatric surgery, at Tirunelveli medical college hospital, Tirunelveli, Tamilnadu, India.

**Study Duration:** January 2022 to June 2023.

**Sample size:** 88 patients.

**Sample size Calculation:** We included all eligible cases reported during the study period (N=88)

**Subjects & Selection Method:** Retrospective collection of data – Children treated for intussusception in our institute during the study period as mentioned above.

### Inclusion Criteria

Intussusception cases proven by ultrasound.

Cases treated by non-operative management (USG guided hydrostatic reduction)

### Exclusion Criteria

Cases treated by primary surgery

Case of peritonitis, intestinal perforation – contraindications for hydrostatic reduction procedure.

## Procedure Methodology

After taking written informed assent from the parents, we included all the cases into the study. All cases were assessed for the history, examination and USG was done for all the cases to confirm the diagnosis.

Successful reduction or failed reduction, duration of hospital stay and mortality were assessed in all the cases.

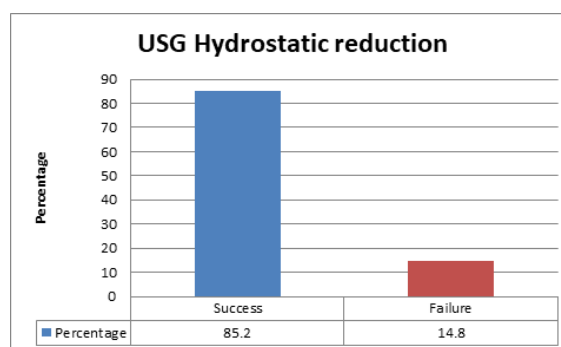
**Statistical Analysis:** Data was entered in Microsoft excel and analyzed using SPSS version 19. Descriptive statistics like frequency, percentages, mean and standard deviations were calculated.

## RESULTS

Mean age of the study participants was found to be  $15.3 \pm 10.5$  months with notable male predominance. [Table 1]

Most common symptoms reported in this study was abdominal pain (76.1%) followed by vomiting (65.9%), abdominal distension (44.3%), blood in stools (35.2%), constipation (43.2%) and diarrhea (34.1%). Additionally 18.2% and 2.3% of cases had mass and lethargy, respectively. Based on USG, all the cases had Ileo colic intussusceptions and 15.9% of cases had free fluids in the abdomen. [Table 2]

All the cases underwent USG hydrostatic reduction however the success rate was reported as 85.2% and the rest of the cases underwent open manual reduction or resection anastomosis. Intra operative finding includes multiple lymph nodes, polyps, lipoma and lymphoma. [Table 3]



**Figure 1: Success rate of USG guided hydrostatic reduction**

**Table 1: Demographic characteristics of study participants**

Variables	Frequency	Percentage
Age groups		
$\leq 6$ months	8	9.1
7- 12 months	31	35.2
13-24 months	33	37.5
24-60 months	14	15.9
$> 60$ months	2	2.3
Gender		
Male	53	60.2
Female	35	39.8

**Table 2: Clinical profile of study participants**

Variables	Frequency	Percentage
Symptoms		
Abdominal Pain	67	76.1
vomiting	58	65.9
Abdominal distension	39	44.3
Blood in stools	31	35.2
Constipation	38	43.2
Diarrhea	30	34.1
Clinical Signs		
Mass	16	18.2
Drowsy/lethargy	2	2.3
USG findings		
Ileo colic intussusception	88	100.0
Free fluids	14	15.9

**Table 3: Success rate of USG hydrostatic reduction**

USG Hydrostatic reduction	Frequency	Percentage
Success	75	85.2
Failure	13	14.8
Failure cases underwent surgical procedures		
Manual reduction	2	15.4
Resection anastomosis	11	84.6
Intra operative findings		
Multiple enlarged lymph nodes	7	53.8
Polyps	4	30.8
Lipoma	1	7.7
Lymphoma	1	7.7

**Table 4: Surgical procedure, hospital stay and mortality among study participants**

Variables	Frequency	Percentage
Duration of hospital stay		
≤ 4 days	38	43.2
5-7 days	46	52.3
> 7 days	4	4.5
Mortality		
Present	0	0
Absent	88	100

## DISCUSSION

The study participants' average age was determined to be 15.3 months, with a clear male predominance. In this study, stomach discomfort was the most frequently reported symptom (76.1%), which was followed by vomiting (65.9%), abdominal distension (44.3%), blood in stools (35.2%), constipation (43.2%), and diarrhoea (34.1%). While USG hydrostatic reduction was performed in all instances, the success rate was only reported to be 85.2%. The other cases had open manual reduction or resection anastomosis. The average hospital stay was 5.3 days, and it's noteworthy that no deaths were recorded. Findings of this study were comparable with the study conducted by Nayak D. et al,<sup>[14]</sup> who discovered that USGHR is simple, secure, and incredibly successful for treating child intussusception. The mortality rate was 1.2%, while the success rate was 81.37%. Enema reduction failed ileo-ileo colic form of intussusception more frequently, although elderly patients had higher success rates with the method. Although early presentation and patients with colo-colic intussusception appear to have higher success rates, this was not statistically significant. Children with primary and recurrent ileo-colic intussusception

underwent hydrostatic reduction that was guided by ultrasonography, according to Demirel BD et al.<sup>[15]</sup> The study included 108 patients with ileo-colic intussusception; 59 of them were men and 49 of them were women, with a mean age of 2.1 years. Without attempting hydrostatic reduction, urgent surgery was performed in two patients. Nineteen patients (18%) were first treated using conservative methods. With expectant care, 17 of them have recovered, and only two patients needed hydrostatic enema reduction during follow-up. Hydrostatic reduction was performed on 89 patients in all, 48 of whom were men and 41 of whom were women, with a mean age of 1.9 years. After hydrostatic reduction failed, twelve patients (13.5%) underwent surgery. One further episode of intussusception is seen in 10 patients (13%) and two extra episodes are seen in 2 patients (2.6%) of the patients who underwent effective hydrostatic reduction. With a mean age of 1.16 years, the seven patients who experienced relapse were male and five were female. The first relapse episode lasted 67.5 days on average. In individuals who had recurrence, the UGHR was also effective.

The effectiveness and safety of UGHR in the treatment of intussusceptions in the paediatric age range are assessed by Ahmed MM et al.<sup>[16]</sup> The age

range of 6 to 24 months saw the highest prevalence of the illness. The most prevalent form was ileo-colic. Time to presentation had an average duration of 17.1 hours. In 90% of cases, the whole therapeutic decrease was accomplished. Within the next 24 hours, there were two recurrences; on the second try, they were successfully decreased. Mortality and complications unrelated to the operation did not happen.

Twenty patients who experienced 21 episodes of intussusception were examined, according to Chukwubuike KE et al.<sup>[17]</sup> Repeat hydrostatic reduction was necessary for one patient because of a recurrence. The majority of the patients (80%) were men. The patients' mean and maximal ages were 8 months and 6 months, respectively. A sizable portion of the patients showed up after their symptoms had started for 48 hours. The main initial symptom was abdominal ache. Prior respiratory and gastrointestinal illnesses were present in 20% and 15% of the patients, respectively, prior to the intussusception. The most frequent type of intussusception was ileo-colic, and its distal end was at the transverse colon. 13 patients (65%) had successful hydrostatic reduction. They asserted that hydrostatic reduction is an easy and successful way to treat intussusception. However, for the best results, early presentation and careful patient selection are required.

Hydrostatic reduction performed while being guided by ultrasound is evaluated by Eraki ME et al,<sup>[18]</sup> and the outcomes are contrasted with those of patients who underwent surgery to address their intussusception. 100 individuals with intussusception were included in this study; there were 60 men and 40 women, ranging in age from 1 month to 7 years. All patients received ultrasound as a diagnostic tool. Thirty patients underwent successful hydrostatic reduction under ultrasound guidance, while twenty patients who were admitted for surgery experienced unsuccessful hydrostatic reduction. Seventy patients underwent open surgery, during which we discovered ileo-ileal intussusception in forty patients, ileo-colic intussusception in twenty patients, and colo-colic intussusception in twenty patients. Twenty-two patients had leading points of intussusception, ten had Meckel's diverticula, five had polyps, and seven had lymphomas. Forty patients underwent manual reduction, and thirty underwent resection anastomosis. Any mortality is nonexistent.

A total of 25 patients who received the operation were assessed, according to Krishnakumar et al.<sup>[19]</sup> 96% of intussusceptions were successfully minimised, according to their research. It generally took 15 minutes. After 24 hours, all patients were checked for recurrence. Within 24 hours, none of them demonstrated recurrence. No problems were noticed. The study comes to the conclusion that hydrostatic reduction with ultrasound guidance is a secure, easy, and efficient way for treating intussusception in children. The effectiveness of ultrasound-guided hydrostatic reduction of intussusception in young patients was evaluated by

Hossain S. et al.<sup>[20]</sup> With no immediate recurrence and no perforation, the overall success rate of US-guided hydrostatic reduction of intussusception in children with early presentation was nearly 90%. They stated that in individuals with early-stage intussusceptions between the ages of 3 months and 2 years old, ultrasound-guided hydrostatic reduction should be the first line of treatment. When an initial reduction attempt fails, a second or even third try may result in a successful reduction.

Retrospective analysis was used by Batos TA et al,<sup>[21]</sup> to examine the success rate of the recently established technique of ultrasound guided hydrostatic reduction in identified ileo-colic intussusceptions. Thirty-one patients underwent ultrasound-guided hydrostatic reduction, while three cases received urgent surgical treatment. All 31 individuals who had non-surgical methods were effective in completely reducing their intussusception. Within the first 48 hours, re-invasion happened in three individuals.

Additionally, Eighty-four intussusception patients were treated during the time period, and 42.9% of those patients were found to be candidates for hydrostatic intussusception reduction, according to Ogunyoyin OO et al.<sup>[22]</sup> Within 48 hours after the onset of symptoms, 66.7% of patients sought treatment. Intussusception hydrostatic reduction was successful in 58.3% of patients while failing in 41.7% of patients. The majority (58%) of the patients under the age of one year and one of the three patients over the age of one year experienced success following the treatment. When symptoms were observed within 48 hours, hydrostatic reduction of intussusception was successful in 58.3% of cases. The effectiveness of ultrasonography (USG)-guided hydrostatic reduction of intussusception with saline and the parameters influencing its success were examined by Avci V et al.<sup>[23]</sup> In 88% of patients, successful reduction was achieved. The median age was 24.83 months, ranging from 20 months for patients whose reduction failed to work to 25.59 months for those whose did. In 94.7% of patients without a history of rectal bleeding and in 83.9% of patients with a history of rectal bleeding, reduction was successful. 4.3 days on average for individuals whose symptoms were successfully reduced, compared to 2.74 days for those whose symptoms were unsuccessfully reduced. In patients whose invaginated segments were successfully reduced, the mean diameter and length were 3.5 cm and 5.12 cm, respectively, and 4.27 cm and 9.23 cm in patients whose invaginated segments were unsuccessfully reduced. Regarding rectal bleeding, vomiting, gender, age, and body weight, there was no discernible difference between the patients who underwent successful and unsuccessful reduction. Additionally, it was discovered that the success rate rose as the number of reduction efforts rose and fell as the length of the symptoms, as well as the diameter and length of the invaginated segment, rose.

Spinola JG et al,<sup>[24]</sup> Assessed the effectiveness of a delayed effort after at least 30 minutes when

reduction has not been fully achieved as well as the therapeutic benefit of an ultrasound guided saline enema for intussusception. Overall, there were 88.2% successful reductions. A delayed attempt that took place at least 30 minutes following the initial partial resolution was successful in 15.5% of the cases. The recurrence rate was 9.7%.

The effectiveness of saline enema-UGHR of intussusceptions in paediatric patients was assessed by Bai YZ et al.<sup>[25]</sup> The reduction success rate for 5218 patients was 95.5%. 4.5 percent had surgery. Nine individuals (0.17%) experienced colonic perforation. Due to vomiting during the hydrostatic enema reduction, two infants experienced milk aspiration. There wasn't any death. They asserted that UGSED of intussusceptions prevents exposure to radiation. It is trustworthy and secure. It is quite successful and rarely causes difficulties. It may be widely applied as standard therapy and is an excellent way for the nonoperative treatment of paediatric intussusception.

In order to examine the efficacy and safety of the hydrostatic and pneumatic reduction approaches, Xie X et al.<sup>[26]</sup> conducted a randomised controlled experiment. This study's overall success rate was 90.32%. Their research revealed that pneumatic reduction with air (83.87%) had a considerably lower success rate than hydrostatic reduction with normal saline (96.8%). Only one member of the pneumatic reduction group had perforation following reduction. Intussusception recurrence rates were 4.84% in the hydrostatic reduction group and 3.23% in the pneumatic reduction group. Also, in another study, Intussusception was primarily noted in children between the ages of 6 and 24 months, according to Digant SM et al.<sup>[27]</sup> 40% of the patients had a history of the common cold, and 80% of the patients had recently experienced gastroenteritis. With a mean duration of 22.1 hours, the transverse colon at the hepatic flexor of the colon was the most often occurring site of intussusception (90%). The mean reduction duration was 14 minutes, and the overall success rate of reductions was 87%. Within 24 hours, no cases indicated recurrence. No problems were noticed.

## CONCLUSION

Ultrasound guided hydrostatic reduction is effective treatment modality option for intussusception, with high success rate & less morbidity. It is a safe and effective treatment modality for intussusception. Furthermore, before embarking on HSR, peritonitis and bowel ischemia should be ruled out clinically and radiologically. In the suspicious cases of bowel ischemia, USG Doppler may be helpful.

## REFERENCES

- Huppertz HI, Gabarro MS, Grimprel E, Franco E, Mezner J, Desselberger U et al (2006) Intussusception among young children in Europe. *Pediatr Infect Dis J* 25:S22–S29
- Charles T, Penninga L, Reurings JC, et al. Intussusception in children: a clinical review. *Acta Chir Belg.* 2015;115(5):327–333.
- Rubinstein JC, Liu L, Caty MG, et al. Pathologic leadpoint is uncommon in ileo-colic intussusception regardless of age. *J Pediatr Surg.* 2015;50(10): 1665–1667.
- Banapour P, Sydorak RM, Shaul D. Surgical approach to intussusception in older children: influence of leadpoints. *J Pediatr Surg.* 2015;50(4):647–650.
- Gangopadhyay AN, Wardhan H (1989) Intestinal obstruction in Children in India. *Pediatr Surg Int* 4(2):84–87
- Mandeville K, Chien M, Willyerd FA, et al. Intussusception: clinical presentations and imaging characteristics. *Pediatr Emerg Care.* 2012;28(9): 842–844.
- Edwards EA, Pigg N, Courtier J, et al. Intussusception: past, present and future. *Pediatr Radiol.* 2017;47(9):1101–1108.
- Verschelden P, Filiatrault D, Garel L, et al. Intussusception in children: reliability of US in diagnosis – a prospective study. *Radiology.* 1992;184(3):601–602.
- Bhisitkul DM, Listermick R, Shkolnik A, et al. Clinical application of ultrasonography in the diagnosis of intussusception. *J Pediatr.* 1992;121(2):182–186.
- Kong MS, Wong HF, Lin SL, et al. Factors related to detection of blood flow by color Doppler ultrasonography in intussusception. *J Ultrasound Med.* 1997;16(2):141–144.
- Choi SO, Park WH, Woo JK. Ultrasound guided water enema: an alternative method of nonoperative treatment for childhood intussusception. *J Pediatr Surg.* 1994;29(4):498–500.
- Del-Pozo G, Albillos JC, Tejedor D, et al. Intussusception in children: current concepts in diagnosis and enema reduction. *Radiographics.* 1999;19(2):299–319.
- Wang GD, Liu SJ. Enema reduction of intussusception by hydrostatic pressure under ultrasound guidance: a report of 377 cases. *J Pediatr Surg.* 1988;23(9):814–818.
- Nayak D, Jagdish S. Ultrasound guided hydrostatic reduction of intussusception in children by saline enema: our experience. *Indian Journal of Surgery.* 2008 Feb;70:8-13.
- Demirel BD, Hancıoğlu S, Dağdemir B, Ceyhan Bilgici M, Yagiz B, Bıçakçı Ü, Bernay F, Arıttürk E. Ultrasound-guided hydrostatic reduction of ileo-colic intussusception in childhood: first-line management for both primary and recurrent cases. *Acta Chirurgica Belgica.* 2022 Jul 4;122(4):248-52.
- Ahmad MM, Wani MD, Dar HM, Mir IN, Wani HA, Raja AN. An experience of ultrasound-guided hydrostatic reduction of intussusception at a tertiary care centre: paediatric surgery. *South African Journal of Surgery.* 2016 Mar 1;54(1):10-3.
- Chukwubuike KE, Nduagubam OC. Hydrostatic reduction of intussusception in children: a single centre experience. *Pan African Medical Journal.* 2020 Aug 11;36(1).
- Eraki ME. A comparison of hydrostatic reduction in children with intussusception versus surgery: Single-centre experience. *African Journal of Paediatric Surgery: AJPS.* 2017 Oct;14(4):61.
- Krishnakumar, Hameed S. Ultrasound guided hydrostatic reduction in the management of intussusception. *The Indian Journal of Pediatrics.* 2006 Mar;73:217-20.
- Hossain MS, Huq MA, Hannan J, Hasina K, Sarker RN. Role of ultrasound-guided hydrostatic reduction of intussusception in children with early presentation. *Journal of paediatric surgeons of Bangladesh.* 2012;3(2):61-4.
- Tripalo Batoš A, Grmoja T, Roič G. Ultrasound-guided reduction of ileocolic intussusception in children. *Pedijatrija Danas: Pediatrics Today.* 2016 Jun 1;12(2).
- Ogundoyin OO, Atalabi OM, Lawal TA, Olulana DI. Experience with Sonogram-guided hydrostatic reduction of Intussusception in Children in South-West Nigeria. *Journal of the West African College of Surgeons.* 2013 Apr;3(2):76.
- Avci V, Agengin K, Bilici S. Ultrasound guided reduction of intussusception with saline and evaluating the factors affecting the success of the procedure. *Iranian Journal of Pediatrics.* 2018 Feb 28;28(1).
- González-Spínola J, Del Pozo G, Tejedor D, Blanco A. Intussusception: the accuracy of ultrasound-guided saline enema and the usefulness of a delayed attempt at reduction. *Journal of pediatric surgery.* 1999 Jun 1;34(6):1016-20.

25. Bai YZ, Qu RB, Da Wang G, Zhang KR, Li Y, Huang Y, Zhang ZB, Zhang SC, Zhang HL, Zhou X, Wang WL. Ultrasound-guided hydrostatic reduction of intussusceptions by saline enema: a review of 5218 cases in 17 years. *The American journal of surgery*. 2006 Sep 1;192(3):273-5.
26. Xie X, Wu Y, Wang Q, Zhao Y, Chen G, Xiang B. A randomized trial of pneumatic reduction versus hydrostatic reduction for intussusception in pediatric patients. *Journal of pediatric surgery*. 2018 Aug 1;53(8):1464-8.
27. Digant SM, Rucha S, Eke D. Ultrasound guided reduction of an ileocolic intussusception by a hydrostatic method by using normal saline enema in paediatric patients: a study of 30 cases. *Journal of clinical and diagnostic research: JCDR*. 2012 Dec;6(10):1722.